

# Spontaneous Rupture of Umbilical Hernia in Pregnancy: A Case Report

Adamu Ahmed, Garba Stephen, Yahaya Ukwenya

Received: 18 May 2011/Accepted: 07 Jul 2011  
© OMSB, 2011

## Abstract

A 28 year old woman presented with a spontaneous rupture of an umbilical hernia in her seventh month of pregnancy. She had four previous unsupervised normal deliveries. There was no history of trauma or application of herbal medicine on the hernia. The hernia sac ruptured at the inferior surface where it was attached to the ulcerated and damaged overlying skin. There was a gangrenous eviscerated small bowel. The patient was resuscitated and the gangrenous small bowel was resected and end to end anastomosis done. The hernia sac was excised and the 12 cm defect repaired. Six weeks later, she had spontaneous vaginal delivery of a live baby. We advocate that large umbilical hernias should be routinely repaired when seen in women of child bearing age.

**Keywords:** Umbilical-hernia; Spontaneous; Rupture; Pregnant-woman; Treatment; Outcome.

## Introduction

Umbilical hernia is a common pathology in both developing as well as the developed countries and accounts for 6% of abdominal wall hernias in adults.<sup>1</sup> In children, these hernias are usually congenital, its diagnosis is easy, as well as its surgical treatment, usually without recurrence. In addition, complications are not common and the hernia may close spontaneously and therefore may not require surgical intervention.<sup>2</sup> Umbilical hernia in adults occurs long after closure of the umbilical ring and is due to a gradual weakening of the cicatricial tissue closing the ring. Predisposing factors to such hernias include obesity, multiple pregnancies with prolonged labor, ascites and large intra-abdominal tumors.<sup>3</sup>

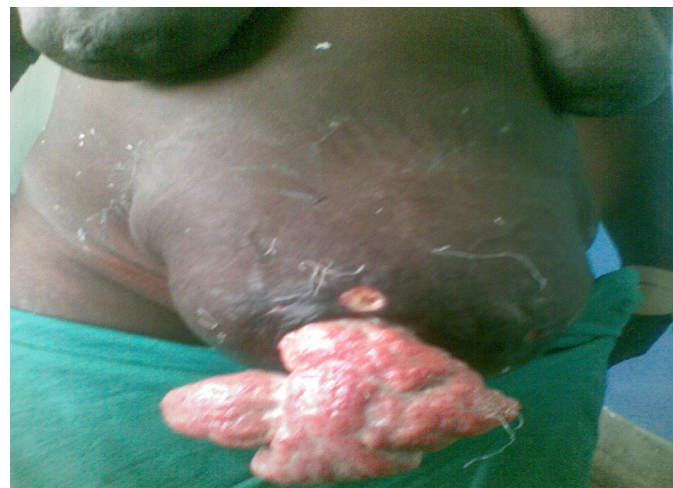In adults, umbilical hernias are frequently symptomatic and are more prone to complications especially in middle-aged multiparous women and patients with cirrhosis. In these patients, the treatment is often more complex and is attended with high morbidity. Spontaneous rupture of umbilical hernia occurs predominantly in cirrhotics.<sup>4</sup> However, there have been sporadic reports of complications of gravid uterus in umbilical hernias.<sup>5-8</sup> In developing countries, patients with emergency surgical problems present late often after complications have developed. We report a

case of spontaneous rupture of umbilical hernia in pregnancy with evisceration and gangrene of small intestine.

## Case Report

A 28 year old woman presented with a spontaneous rupture of an umbilical hernia in her seventh month of unsupervised pregnancy. She had four previous unsupervised pregnancies and her previous obstetrics history was normal. She had an umbilical hernia since childhood which had increased gradually with the number of pregnancies. She never had symptoms suggestive of obstruction of the hernia which always reduced spontaneously when she lied supine. The rupture of the hernia was not associated with coughing, trauma or topical application of herbal medicine.

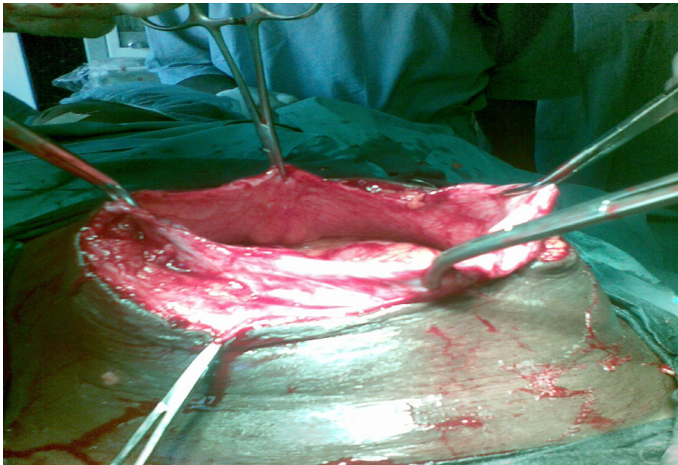
The gravid uterus was in the hernia sac at the time of rupture. On examination, she was pale and in shock. Her pulse rate was 146/minute and thready and systolic blood pressure was 70 mmHg. Chest examination did not reveal any abnormality. There was a ruptured umbilical hernia with eviscerated ileum that was dark and not peristalsing, (Fig. 1). There were ulcers on the superior and inferior surfaces of the skin covering the hernia. The gravid uterus was palpable at 28 weeks gestation. The foetal heart rate was 140/minute and regular. An assessment of spontaneous rupture of umbilical hernia in pregnancy was made. Hematocrit was 25% and serum urea and electrolytes were normal. Abdominal ultrasound showed a single foetus with maturity of approximately 27 weeks. She was resuscitated with intravenous fluid, nasogastric tube suction and urethral catheterization. Analgesics, antibiotics and tetanus toxoid were also given.



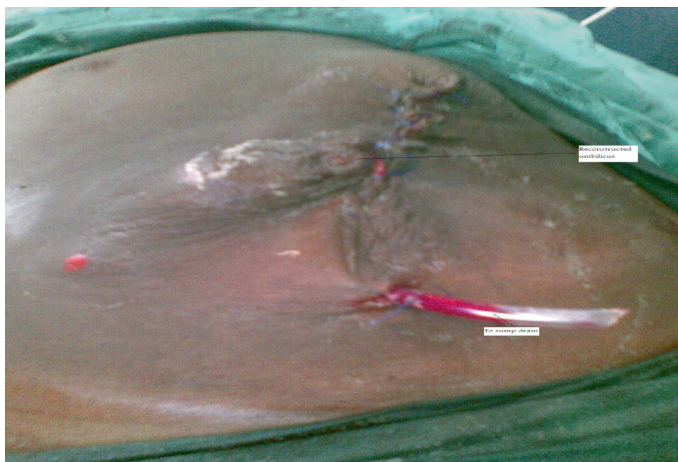**Figure 1:** Ruptured umbilical hernia with eviscerated bowel in a pregnant woman.

Adamu Ahmed ✉, Garba Stephen, Yahaya Ukwenya  
Department of Surgery, Ahmadu Bello University Teaching Hospital, Zaria  
Nigeria.  
Email: mrahmed1010@yahoo.com

The eviscerated bowel was covered with sterile gauze soaked in warm normal saline. At laparotomy, there was a 30 cm of gangrenous ileum 36 cm from the ileo-caecal junction. The uterus and other abdominal viscera were normal. Resection of the gangrenous ileum and end to end anastomosis was done. The hernia sac and overlying skin were excised and the 12 cm hernia defect, (Fig. 2) was repaired by approximating the linea alba transversely with nylon one. The umbilicus was reconstructed by purse-string umblicoplasty, (Fig. 3). The patient did well postoperatively. Six weeks later, she went into spontaneous labour and had assisted vaginal delivery of a live baby. She had remained well at nine months follow-up.



**Figure 2:** Excised overlying skin and hernia sac



**Figure 3:** Patient with umbilical hernia immediately after surgery. Note the reconstructed umbilicus

## Discussion

The neck of an umbilical hernia is usually relatively narrow compared to the size of the sac which may be large and protruding forwards and downwards to overhang the pubis. The presence of gravid uterus within umbilical hernia is very rare because the uterus is usually too large to enter the sac by the time it reaches that level.<sup>5</sup> While the risk of complications of umbilical hernias still exists during pregnancy, the enlarging uterus may in theory protect against incarceration by physically blocking the intra-abdominal contents from the inlet of the defect. However, if the hernia neck is larger, the gravid uterus is easily carried into the sac especially when the anterior abdominal wall is lax due to flabbiness

of the abdominal muscles associated with repeated pregnancies.<sup>5</sup> Spontaneous rupture of umbilical hernia usually occurs in infants and is precipitated by a sudden rise in intra abdominal pressure or damage to overlying skin.<sup>2</sup>

Wydell reported a case in which the rupture occurred in labour during bearing down and was deep enough to expose the peritoneum.<sup>8</sup> In our patient, rupture was probably precipitated by damage to overlying skin which was stretched, thinned and ulcerated. This is due to ischemia resulting from pressure by the gravid uterus. In addition, there is a continuous friction between the hernia and the abdominal wall, which in combination with sweaty moisture and warmth cause large areas of ulcerations and dermatitis. In some patients, the umbilical hernia is treated by the application of traditional herbal medicines which often cause inflammation, necrosis and sometimes gangrene of the skin resulting in decubitus ulcers which may precipitate spontaneous rupture of the hernia.<sup>7</sup> In our patient, the sac ruptured at the inferior surface which was the most dependant part and the site attached to the overlying inflamed, ulcerated and damaged skin. Repair of the hernia was safe as in another report but may be difficult due to tissue attenuation from pressure.<sup>6</sup> During labour, the second stage was assisted in order to prevent excessive pressure on the recently repaired hernia during bearing down.

It has been reported that umbilical hernia can be safely repaired at the time of caesarean section. However, we did not offer caesarean section to our patient because the baby was premature at the time of surgery. When the hernia presents during pregnancy, repair should be deferred until as soon as possible post partum after involution of the uterus unless it is complicated by rupture, strangulation or incarceration.<sup>9</sup> This is because surgery during pregnancy could precipitate uterine irritability and induce premature labour. In addition, induction of collagen remodelling by relaxin during pregnancy soften the tissues thereby predisposing to hernia recurrence.<sup>10</sup>

The type of surgical repair that should be offered to patients with umbilical hernia remains a matter of dispute and various surgical techniques such as primary suture, Mayo repair, mesh repair, and laparoscopic surgery have been used for the treatment of this surgical condition.<sup>11,12</sup> Laparoscopic approach is faster and is associated with less complications and recurrence compared to open umbilical hernia repair.<sup>11</sup> In addition, laparoscopic approach is associated with less postoperative pain and faster recovery than open techniques.<sup>11</sup> However, it is not cost effective for the defect of <2 cm that can be safely treated by the open method. The use of prosthetic material for open umbilical hernia repair has been reported to reduce recurrence rates.<sup>12</sup> In our patient, the hernia defect was large (12 cm) but was repaired by the Mayo overlap method because mesh was not available at the time of surgery. The suture repair of a large defect in our patient may result in tissue tension which is associated with high recurrence. In addition, such repair may cause raised intra-abdominal pressure particularly in our patient whose abdomen contained a gravid uterus. This can lead to respiratory complications such as atelectasis and pneumonia

that were prevented by chest physiotherapy and early ambulation.

Large differences in hernia recurrence rates have been reported depending on surgical technique, hernia defect of >2 cm and length of follow-up.<sup>13,14</sup> Halm et al. reported a recurrence rate of 54% after simple suture repair.<sup>14</sup> In another study, the recurrence rate was 2.8% for the suture repair group compared to no recurrence in the mesh group.<sup>15</sup> Although follow-up was limited to nine months in our patient, there was no recurrence of the hernia. However, previous studies have shown that most recurrences occur within the first three months after repair.<sup>12,14</sup>

In sub-Saharan Africa where the incidence of umbilical hernia is high, the otherwise rare complications of umbilical hernia may be seen more frequently. Premature labour, intrauterine foetal death and secondary hemorrhage have been reported in connection with gravid uterus in anterior abdominal wall hernia.<sup>16</sup> These complications may also occur with gravid uterus in umbilical hernia.

## Conclusion

It is important to repair these hernias before complications occur. To reduce pregnancy related morbidity obstetric services should be made available, accessible and affordable in keeping with primary care objectives. In addition, umbilical hernia should be electively repaired as soon as possible in women of child bearing age. This would reduce the morbidity, mortality and recurrences associated with emergency repair of these hernias.

## Acknowledgements

The authors reported no conflict of interest and no funding was received on this work.

## References

- Perrakis E, Velimezis G, Vezakis A, Antoniadis J, Savanis G, Patrikakos V. A new tension-free technique for the repair of umbilical hernia, using the Prolene Hernia System—early results from 48 cases. *Hernia* 2003 Dec;7(4):178-180.
- Ahmed A, Ahmed M, Nmadu PT. Spontaneous rupture of infantile umbilical hernia: report of three cases. *Ann Trop Paediatr* 1998 Sep;18(3):239-241.
- Muschaweck U. Umbilical and epigastric hernia repair. *Surg Clin North Am* 2003 Oct;83(5):1207-1221.
- Armstrong O. Umbilical hernia. *Rev Prat* 2003 Oct;53(15):1671-1676.
- Hassim AM, Khurana KM. Gravid uterus in an umbilical hernia. *Cent Afr J Med* 1967 Nov;13(11):260-261.
- Castro MN, Saavedra AB. A pregnant uterus protruding through an umbilical hernia sac. *S Afr Med J* 1975;49:1174.
- Adetoro OO, Konalafe F. Gravid uterus in an umbilical hernia: Report of 2 cases. *Cent Afr J Med* 1987;32:248-251.
- Wydell SH. Umbilical hernia in pregnancy. *Br Med J* 1963 May;1(5342):1413-1414.
- Uludag M, Yetkin G, Demirel M, Citgez B, Isgor A. Incarceration of umbilical hernia during pregnancy due to a sessile fibroid. *Hernia* 2006 Aug;10(4):357-359.
- Ochsenbein-Kölbl N, Demartines N, Ochsenbein-Imhof N, Zimmermann R. Cesarean section and simultaneous hernia repair. *Arch Surg* 2004 Aug;139(8):893-895.
- Gonzalez R, Mason E, Duncan T, Wilson R, Ramshaw BJ. Laparoscopic versus open umbilical hernia repair. *JLS* 2003 Oct-Dec;7(4):323-328.
- Arroyo A, García P, Pérez F, Andreu J, Candela F, Calpena R. Randomized clinical trial comparing suture and mesh repair of umbilical hernia in adults. *Br J Surg* 2001 Oct;88(10):1321-1323.
- Venclauskas L, Silanskaite J, Kiudelis M. Umbilical hernia: factors indicative of recurrence. *Medicina (Kaunas)* 2008;44(11):855-859.
- Halm JA, Heisterkamp J, Veen HF, Weidema WF. Long-term follow-up after umbilical hernia repair: are there risk factors for recurrence after simple and mesh repair. *Hernia* 2005 Dec;9(4):334-337.
- Ghannam WM, Helal AS, Fawzy M, Ragab A, Shalaby H, Elrefaay E. Paraumbilical hernia repair during cesarean delivery. *Ann Saudi Med* 2009 Mar-Apr;29(2):115-118.
- Singla SL, Kalra U, Singh B, Narula S, Dahiya P. Ruptured incisional hernia. *Trop Doct* 1997 Apr;27(2):112-113. *Trop Doct*. 1997; 27: 112-113.