

Chondroid Lipoma: A Case Report

Uday Gokhale,¹ G. Rajasekharan Pillai,¹
P.V. Varghese,² D. Samarsinghe³

Abstract

Chondroid lipoma is a unique, uncommon benign lipomatous tumour. Due to distinct morphological similarity, it is important to distinguish it from extraskeletal chondrosarcoma and myxoid/round cell liposarcoma (MRCLS). We report such a neoplasm with brief a review of literature.

Received: 11 August 2007

Accepted: 29 October 2007

From the ¹Department of Pathology, ²Department of Surgery, Sultan Qaboos Hospital, Salalah, Oman, ³Department of Histopathology, Royal Hospital, Muscat, Sultanate of Oman.

Address correspondence and reprint request to: Dr. Uday Gokhale, Department of Pathology, Sultan Qaboos Hospital, Salalah, Sultanate of Oman.

E-mail: uday_gokhale@rediffmail.com

Introduction

Lipomatous tumours represent one of the most common neoplastic growths encountered by pathologists. The spectrum ranges from the common benign solitary lipoma to malignant liposarcoma. Chondroid lipoma had not been defined until 1993. Meis and Enzinger¹ coined this term to reflect the histological pattern of the tumour which contains two components – adipose tissue with mature fat cells and lipoblasts and cartilaginous tissue with chondroblasts and hyaline matrix. Because of the cellularity and morphology of cells it can be misdiagnosed as sarcoma especially liposarcoma and chondrosarcoma.² Hence familiarity with the features of chondroid lipoma is of practical importance to avoid an overdiagnosis and subsequent overtreatment.³

Case Report

A 43 year old female patient presented with a painless slowly increasing growth on the dorsum of her forearm. An excision biopsy was done and subjected to histopathological examination.

Gross Pathology

Macroscopic examination revealed a single, oval, well encapsulated yellow mass measuring 2.8 x 1.7 x 1.1 cms. The cut surface was yellowish with lobulated appearance and rubbery consistency.

Histologic findings

H&E sections showed an encapsulated neoplasm composed of cells arranged in a myxoid, hyalinised or cartilaginous matrix. Three types of cells were identified viz, mature fat cells, lipoblast like cells with vacuolated cytoplasm and central nuclei and oval or round cells with eosinophilic cytoplasm. Though there was mild pleomorphism, no significant mitotic activity noted. Tumour cells showed S-100 protein positivity in immunohistochemistry. With this classical histological pattern, a diagnosis of chondroid lipoma was rendered.

Discussion

Chondroid lipoma is a rare fatty tumour of soft tissue usually presenting as a painless mass, occurring in superficial or deeper tissues. Most lesions are situated in the subcutis, superficial muscular fascia or skeletal muscles of the limbs and limb girdles, trunk and head and neck.¹ They may reach considerable size, adding to the risk of misdiagnosing them as sarcomas. There is predilection for adult women but can also occur in the paediatric age group.⁴

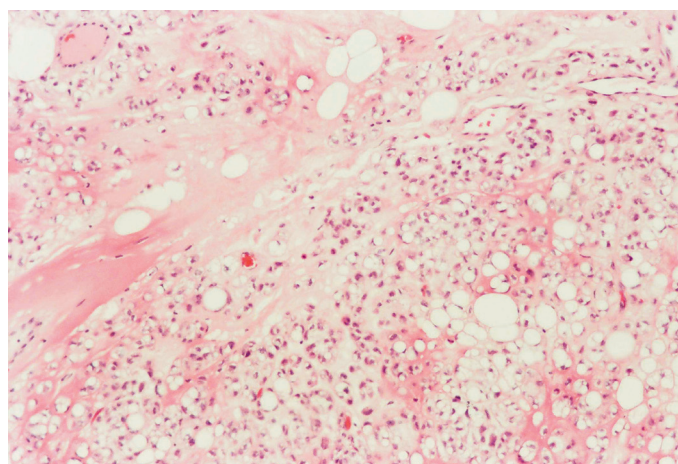


Figure 1: Small groups and single multivacuolated tumour cells surrounded by hyalinised or cartilaginous matrix admixed with mature appearing adipocytes. (H&E x 100)

Histologically, chondroid lipomas are well circumscribed tumours consisting of mature adipocytes in common lipoma like areas and of a chondroid component in which vacuolated lipoblast like cells are surrounded by myxohyaline matrix. Both components are connected and mutually transient.⁵ The vacuoles can be shown to contain lipids using Oil red O stain and glycogen using Periodic Acid-Schiff stain. Presence of stromal mucins support chondroid differentiation.¹

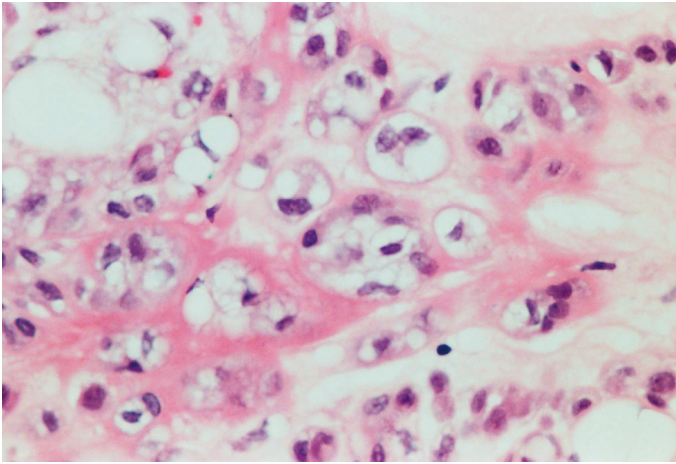


Figure 2: Tumor cells with central irregular nuclei surrounded by clear, vacuolated cytoplasm resembling lipoblasts. (H&E x 400)

Immunohistochemically, the tumour cells stain for S-100 protein, Vimentin and CD-68. Focal positivity for keratin is reported in some of the cases.³ Ultrastructural studies have shown that chondroid lipomas are truly biphenotypic with lipoblastic differentiation and features of primitive cartilage.⁴

Though chondroid lipoma is a clinically benign neoplasm the main importance lies in its histological similarity with liposarcoma and chondrosarcoma, which have a poorer prognosis.⁶ Myxoid liposarcoma can be distinguished from it by absence of plexiform

vascular pattern and presence of chondroid-like but not myxoid matrix. Extraskeletal chondrosarcoma does not contain adipocytes or lipoblast-like cells as a component of the tumour.² A diagnosis of sarcoma entails consideration of radical surgery and post-operative radiotherapy while chondroid lipoma in contrast is cured by surgical resection.⁷

References

1. Meis JM, Enzinger FM. Chondroid lipoma. A unique tumor simulating liposarcoma and myxoid chondrosarcoma. *Am J Surg Pathol* 1993 Nov;17(11):1103-1112.
2. Nielsen GP, O'Connell JX, Dickersin GR, Rosenberg AE. Chondroid lipoma, a tumor of white fat cells. A brief report of two cases with ultrastructural analysis. *Am J Surg Pathol* 1995 Nov;19(11):1272-1276.
3. Mentzel T, Remmler K, Katenkamp D. Chondroid lipoma. Clinicopathological, immunohistochemical, and ultrastructural analysis of six cases of a distinct entity in the spectrum of lipomas. *Pathologe* 1999 Nov;20(6):330-334.
4. Kindblom LG. Lipomatous tumors-how we have reached our present views, what controversies remain and why we still face diagnostic problems: a tribute to Dr Franz Enzinger. *Adv Anat Pathol* 2006 Nov;13(6):279-285.
5. Zámečník M, Michal M, Fakan F. Chondroid lipoma. *Cesk Patol* 1996 Aug;32(3):115-117.
6. Manna AK, Chattopadhyay A, Chowdhury K, Chowdhury MK, Dutta SK. Chondroid lipoma—a case report. *Indian J Pathol Microbiol* 2006 Jul;49(3):422-424.
7. Vasili C, Kligman M, Kirsh G. Incidental finding of chondroid lipoma at total hip arthroplasty. *J South Orthop Assoc* 2000;9(3):219-221.