

## Syncopal Attacks and Severe Abdominal Pain

Khalifa N. AlWahaibi<sup>1</sup> and Faisal H. Al-Azri<sup>2</sup>

From the <sup>1</sup>Department of Surgery; <sup>2</sup>Departments of Radiology and Molecular Imaging, Sultan Qaboos University Hospital, Al Khoud, Muscat, Sultanate of Oman.

Received: 07 Feb 2010

Accepted: 28 Apr 2010

Address correspondence and reprint request to: Dr. Khalifa Al-Wahaibi, General and Vascular Surgery, Department of Surgery, Sultan Qaboos University Hospital, Al-Khod, Sultanate of Oman.  
E-mail : dralwahaibi@hotmail.com

doi:10.5001/omj.2010.91

**A** 54 years old male, chronic smoker, hypertensive on beta blocker presented to the emergency room with a history of syncopal attacks from early morning followed by severe abdominal and back pain lasting for four hours. There was no history of trauma, fever or change in bowel habits.

On physical examination, the patient was drowsy with a heart rate of 70 beats per minute and blood pressure of 60/30 mmHg. The abdomen was distended with mild tenderness. No pulsatile abdominal mass was felt and no audible abdominal bruit was heard. Femoral and distal pulses were palpable. Both his feet were cold to touch. An urgent CT scan with intravenous contrast was done.

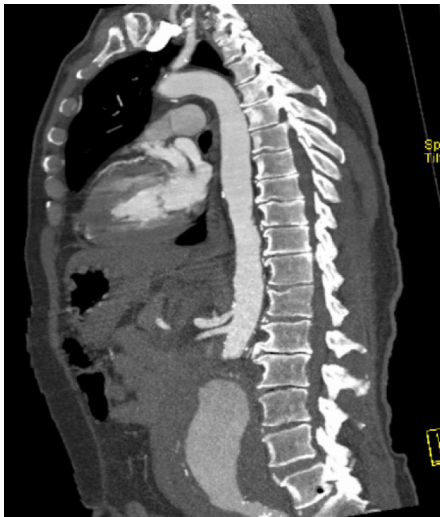

Figure 1: A sagittal CT scan view

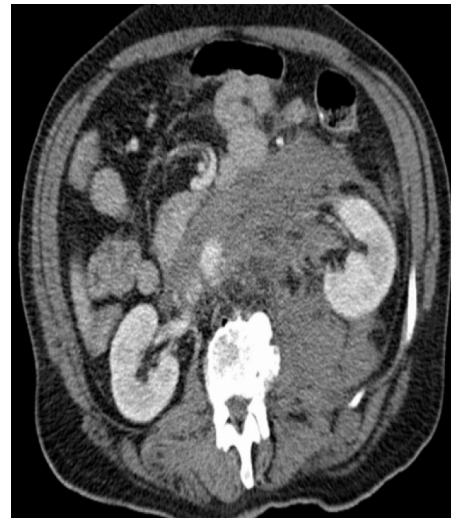

Figure 2: An axial CT scan view

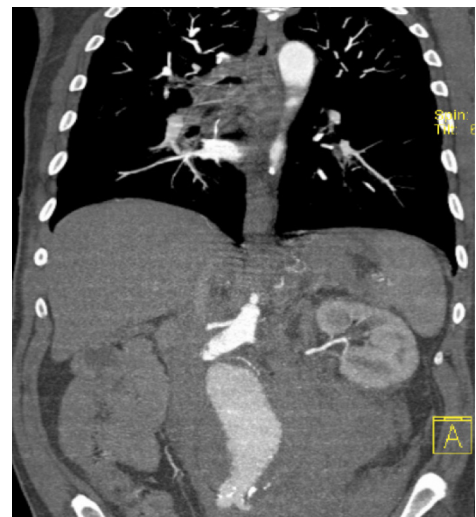


Figure 3: A coronal CT scan view

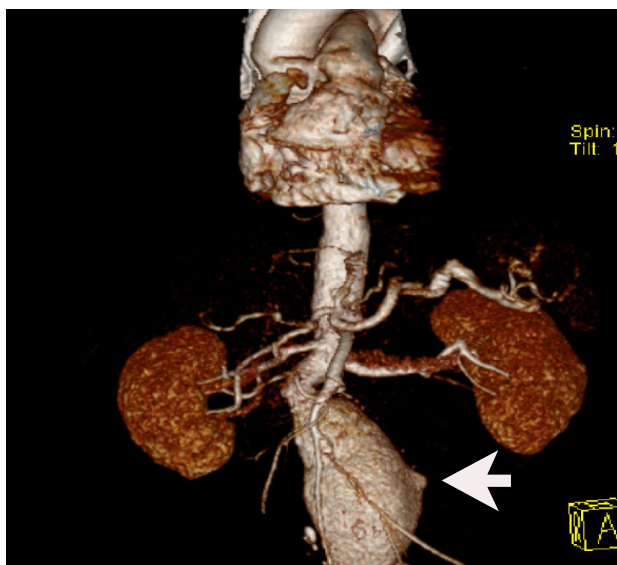
### Questions

1. What are the CT scan findings?
2. What is your diagnosis?
3. What are your treatment options?

Answers on page 319

### Answers

1. An infra-renal abdominal aortic aneurysm with an extensive retroperitoneal hematoma extending above the renal arteries
2. A ruptured infra-renal abdominal aortic aneurysm
3. - Open abdominal aortic repair  
- Endovascular abdominal aortic repair (EVAR)



**Figure 4:** A three dimensional reconstruction image of the CT scan showing a 6 cm infra-renal abdominal aortic aneurysm with a bleb; the possible site of the rupture (arrow).

### Discussion

Abdominal Aortic Aneurysm Rupture is defined as disruption of a dilated aortic wall that leads to leaking (extravasation) of blood outside the aortic wall. Ruptured Abdominal Aortic Aneurysm is classified into retroperitoneal and free rupture. Free rupture is defined as direct rupture into the peritoneal cavity or secondary to the failure of the retroperitoneum to contain the hematoma. The prognosis of free rupture is significantly worse because of the larger amount of bleeding that can occur intraperitoneally.<sup>1</sup>

Aortic rupture is a lethal event. The mortality rate for patients who arrive at hospital alive ranges from 40% to 70%.<sup>2</sup> When autopsy data are taken into account, including patients who die before reaching the hospital, the mortality rate is 90%.<sup>3</sup>

The classic triad for Ruptured Abdominal Aortic Aneurysm presentation is severe abdominal or back pain, hypotension, and a pulsatile mass.<sup>4</sup> The pulsatile mass often is obscured in patients with large abdominal girth. Syncope may indicate an episode of hypotension. A clinical history that suggests this combination of symptoms mandates consideration of Ruptured Abdominal Aortic Aneurysm and steps to rule out this diagnosis.

Currently, open surgical repair is the standard treatment for Ruptured Abdominal Aortic Aneurysm. Endovascular aortic repair (EVAR) is being increasingly reported and several single-center publications have suggested that repair of ruptured abdominal aortic aneurysm by endovascular techniques (EVAR) may be a significant advance in reducing the mortality, morbidity, and length of stay for Ruptured Abdominal Aortic Aneurysm.<sup>5-8</sup> Special considerations required to perform EVAR for Ruptured Abdominal Aortic Aneurysms include rapid availability of CT scanning, a team of trained personnel, a stock of devices, and the proper suite in which to perform the procedure.

A meta-analysis of the 50 years of Ruptured Abdominal Aortic Aneurysm repair included 171 articles, which provided sufficient information so that mortality rates could be determined. The overall operative mortality was 48%. The intra-operative mortality was 15%, and the postoperative mortality after successful surgery was 40%.<sup>9</sup>

Due to unavailability of endovascular repair technique in our institute, the patient underwent an open aortic repair. Proximal vascular control was obtained at supra-celiac position and the aorta was repaired using a tube Dacron graft. The patient is surviving his eighth post operative week with marked gradual improvement.

### Acknowledgements

The authors reported no conflict of interest and funding has been received on this work.

### References

1. Glowiczki P, Pairolero PC, Mucha P Jr, Farnell MB, Hallett JW Jr, Ilstrup DM, et al. Ruptured abdominal aortic aneurysms: repair should not be denied. *J Vasc Surg* 1992 May;15(5):851-857, discussion 857-859.
2. Lawrence PF, Gazak C, Bhirangi L, Jones B, Bhirangi K, Oderich G, et al. The epidemiology of surgically repaired aneurysms in the United States. *J Vasc Surg* 1999 Oct;30(4):632-640.
3. Bengtsson H, Bergqvist D. Ruptured abdominal aortic aneurysm: a population-based study. *J Vasc Surg* 1993 Jul;18(1):74-80. PubMed </jrn>
4. Marston WA, Ahlquist R, Johnson G Jr, Meyer AA. Misdiagnosis of ruptured abdominal aortic aneurysms. *J Vasc Surg* 1992 Jul;16(1):17-22.
5. Brandt M, Walluscheck KP, Jahnke T, Graw K, Cremer J, Müller-Hülsbeck S. Endovascular repair of ruptured abdominal aortic aneurysm: feasibility and impact on early outcome. *J Vasc Interv Radiol* 2005 Oct;16(10):1309-1312.
6. Alsac JM, Desgranges P, Kobeiter H, Becquemin JP. Emergency endovascular repair for ruptured abdominal aortic aneurysms: feasibility and comparison of early results with conventional open repair. *Eur J Vasc Endovasc Surg* 2005 Dec;30(6):632-639.
7. Vaddineni SK, Russo GC, Patterson MA, Taylor SM, Jordan WD Jr. Ruptured abdominal aortic aneurysm: a retrospective assessment of open versus endovascular repair. *Ann Vasc Surg* 2005 Nov;19(6):782-786.
8. Larzon T, Lindgren R, Norgren L. Endovascular treatment of ruptured abdominal aortic aneurysms: a shift of the paradigm? *J Endovasc Ther* 2005 Oct;12(5):548-555.
9. Bown MJ, Sutton AJ, Bell PR, Sayers RD. A meta-analysis of 50 years of ruptured abdominal aortic aneurysm repair. *Br J Surg* 2002 Jun;89(6):714-730.