

# Late Post Traumatic Right-sided Diaphragmatic Hernia Presenting with Acute Intestinal Obstruction and Strangulation: A Rare Presentation

Shahbaz Habib Faridi, Amjad Ali Rizvi, Bushra Siddiqui, Mohd Khalid

Received: 17 Oct 2012 / Accepted: 10 Dec 2012  
© OMSB, 2013

## Abstract

We report a case of 16 year old male, who was presented to Jawaharlal Nehru Medical College, AMU, Aligarh, India as an emergency case with complaints of severe abdominal pain, difficulty in breathing and bilious vomiting. He was diagnosed as a case of late post traumatic right side diaphragmatic hernia with acute intestinal obstruction. He was successfully treated surgically by laparotomy and the defect was closed with polypropylene suture. The patient was followed for 3 months after operation and there was no complication.

**Keywords:** Late Diaphragmatic Hernia, Acute Intestinal Obstruction, Strangulation.

## Introduction

The early diagnosis of post-traumatic diaphragmatic lesions is often difficult, which explains the 30 to 50% of non-diagnosed cases.<sup>1</sup> Traumatic injuries of the diaphragm are uncommon, and it is difficult to establish the exact incidence, but by autopsy studies, the incidence of these injuries range between 5.2% and 17%.<sup>2</sup> Only 0.8% to 1.6% of the total lesions observed in these patients are due to blunt trauma.<sup>3</sup> Post-traumatic diaphragmatic hernia is a particular lesion in traumatology that may be neglected.<sup>4</sup> Besides the clinical signs and the modality of presentation, the lesions appear absolutely nonspecific.<sup>5</sup> Incorrect interpretation of the X-ray or only intermittent hernial symptoms are frequent reasons for incorrect diagnosis.<sup>6</sup> Also the initial non-recognition of the possible manifestation of the diaphragmatic hernia following blunt or penetrating injuries is usually because the practitioner has not sought it. Thus, the diagnosis may be delayed for a few days to several months and only be made following a complication. Review of the historical clinical literature, including the series of Carter et al reveals that the majority (80-90%) of blunt diaphragmatic ruptures have occurred on the left side. They required greater force

of impact, possibly because the liver provides protection or because of a weakness in the left diaphragm.<sup>7</sup> Obstruction can occur in diaphragmatic hernias but strangulation is rare.<sup>8</sup>

## Case Report

A 16 yr old boy presented as an emergency case with complaints of vomiting, abdominal pain and difficulty in breathing. We learned from the patient's history that he had been run over the chest by a motor vehicle 11 years back and since then he has been having episodes of dyspnea. The colour of the vomitus was bilious. On examination there was decreased air entry on the right side of the chest and bowel sounds were present in the right hemithorax which were exaggerated. Radiographs of the chest were suggestive of bowel loops in the right hemithorax and radiographs of abdomen were suggestive of multiple air fluid levels and distension of the small bowel.

Emergency laparotomy was done by midline incision. Terminal ileum and transverse colon along with liver was present in the right hemithorax and there were pregangrenous changes in the terminal ileum. There was a defect in the right diaphragmatic cupola present posteriorly and ipsilateral lung was collapsed. Adhesions were present in the small bowel and the transverse colon. The bowel loops were free and slowly the color of the bowel became normal. The liver was mobilized and the diaphragmatic rent was closed using polypropylene sutures. There was no tension over the rent after the repair. Intercostal tube drainage was done on the right side. Conversion to thoracotomy was not done as the contents were easily mobilized by laparotomy. The patient was followed for 3 months post operation and there was no complication.

## Discussion

Traumatic Diaphragmatic Hernias usually result from severe external blunt injury or penetrating injuries such as a knife or bullet wound. The hernias may be recognized during the period of hospitalization immediately following the trauma, the immediate type of hernia is described by Carter et al.<sup>7</sup> However, it is widely accepted that herniation may be delayed.

If the diaphragmatic injury is not recognized during the immediate post-traumatic period, the patient may: 1) recover and remain symptom free; 2) suffer from chronic abdominal and/or

Shahbaz Habib Faridi , Amjad Ali Rizvi  
Department Of Surgery, JN Medical College  
E-mail: shahbazfaridi@yahoo.com

Mohd Khalid  
Department Of Radiodiagnosis, JN Medical College

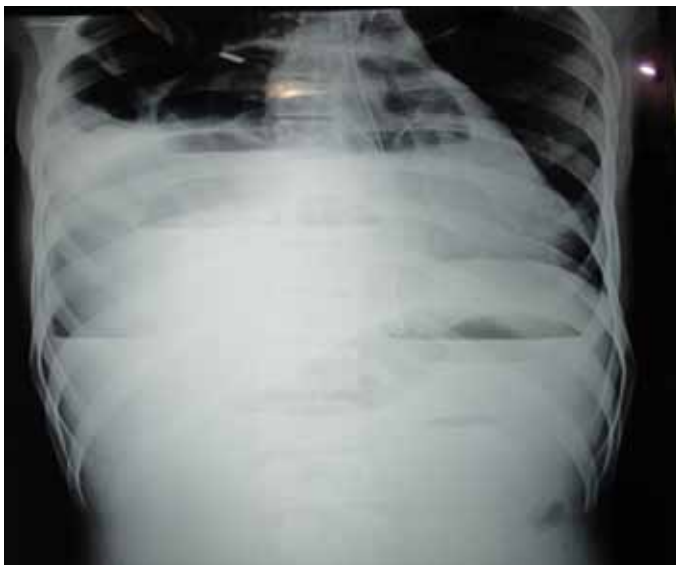Bushra Siddiqui  
Department of Pathology, JN Medical College

chest symptoms, or 3) present with an acute crisis, often with signs of intestinal obstruction or strangulation.<sup>9</sup>

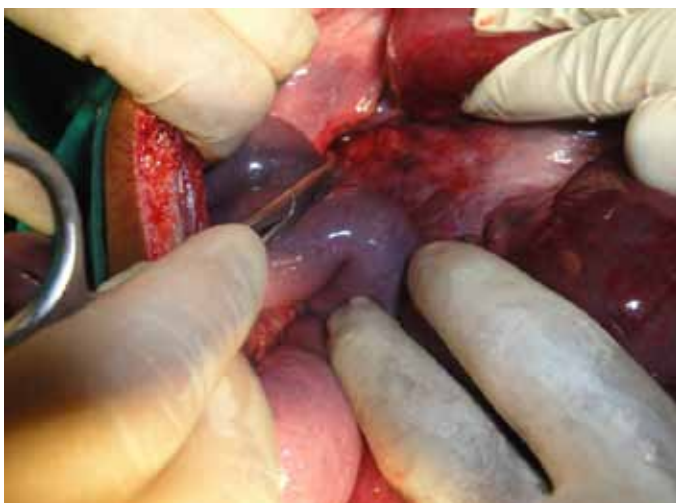In a review of 276 patients with traumatic diaphragmatic hernia, Hood found only 13% on the right side.<sup>10</sup> This is probably due to the liver cushioning the diaphragm in blunt trauma and plugging the defect in the penetrating trauma.

## Conclusion

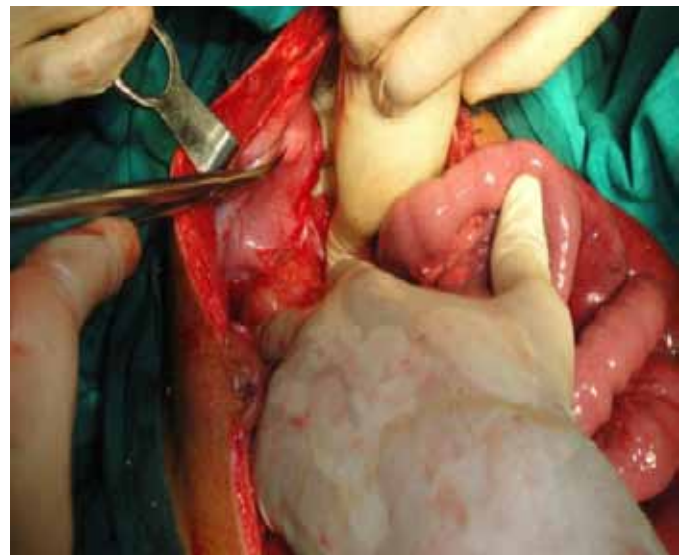
Recognition of a traumatic diaphragmatic hernia in the immediate post-traumatic period is difficult, due to associated injuries and to the fact that several radiological features suggestive of hernia may mimic those of chest injuries. A careful history, examination, and awareness of the possibility of the condition and its complications are essential if these patients are to be managed successfully.



**Figure 1:** Radiograph of the patient showing right side diaphragmatic hernia with multiple air fluid levels in small intestine suggestive of Acute Intestinal Obstruction.



**Figure 2:** Operative photograph of the patient showing diaphragmatic rupture and pregangrenous condition of bowel loops.



**Figure 3:** Mobilization and adhesiolysis of transverse colon, small bowel regaining its color after being taken out from thoracic cavity.

## Acknowledgements

The author reported no conflict of interest and no funding was received in this work.

## References

1. Seket B, Henry L, Adham M, Partensky C. Right-sided posttraumatic diaphragmatic rupture and delayed hepatic hernia. *Hepatogastroenterology* 2009 Mar-Apr;56(90):504-507.
2. Reber PU, Schmied B, Seiler CA, Baer HU, Patel AG, Büchler MW. Missed diaphragmatic injuries and their long-term sequelae. *J Trauma* 1998 Jan;44(1):183-188.
3. Mansour KA. Trauma to the diaphragm. *Chest Surg Clin N Am* 1997 May;7(2):373-383.
4. Kafh M, Boufettal R. [A late post-traumatic diaphragmatic hernia revealed by a tension fecopneumothorax (a case report)]. *Rev Pneumol Clin* 2009 Feb;65(1):23-26. [www.pubmed.gov](http://www.pubmed.gov). Accessed 28 Nov 2011. Published online 2009.
5. De Blasio R, Maione P, Avallone U, Rossi M, Pigna F, Napolitano C. [Late posttraumatic diaphragmatic hernia. A clinical case report]. *Minerva Chir* 1994 May;49(5):481-487.
6. Rashid F, Chakrabarty MM, Singh R, Iftikhar SY. A review on delayed presentation of diaphragmatic rupture. *World J Emerg Surg* 2009;4:32.
7. Carter BN, Giuseffi J, Felson B. Traumatic diaphragmatic hernia. *Am J Roentgenol Radium Ther* 1951 Jan;65(1):56-72.
8. Singh S, Wakhlu A, Pandey A, Kureel SN, Rawat JD. Hernia 2011. Available at [www.springerlink.com](http://www.springerlink.com). Accessed on April 26, 2012.
9. Hegarty MM, Bryer JV, Angorn IB, Baker LW. Delayed presentation of traumatic diaphragmatic hernia. *Ann Surg* 1978 Aug;188(2):229-233.
10. Hood RM. Traumatic diaphragmatic hernia. *Ann Thorac Surg* 1971 Sep;12(3):311-324.