



Desquamative Lesion of the Nose and Lip

Manas Bajpai

Department of Oral and Maxillofacial Pathology, NIMS Dental College, Jaipur, India

ARTICLE INFO

Article history:

Received: 7 July 2017

Accepted: 17 July 2017

Online:

DOI 10.5001/omj.2018.16

A 28-year-old male presented to the Department of Oral Medicine and Radiology for the evaluation of multiple asymptomatic erythematous lesions on the ala of nose and lips, which he noticed one year ago. He had no history of fever, joint pain, cough, weight loss, eye complaints, or any other systemic complaints. Past and family history were not contributory. There was no significant drug history. General physical and systemic examinations were normal.

Facial examination revealed a large erythematous lesion extending from the ala to the apex of the nose measuring 3 × 2 cm. Another lesion was seen on the upper lip [Figure 1]. Chest X-ray, routine hemogram, serum, and 24-hour urinary calcium

were normal. Mantoux test was negative. Slit skin smears for acid-fast bacilli and *Leishmania donovani* bodies were negative. An incisional biopsy under local anesthesia was performed from the ala of the nose for microscopic evaluation, which revealed non-caseating granulomas comprised of epithelioid cells and few Langhans giant cells with focal areas of lymphocytic infiltration [Figure 2].

Question

1. What is the diagnosis?

- Tuberculosis.
- Sarcoidosis.
- Lupus pernio.
- Leishmaniasis.

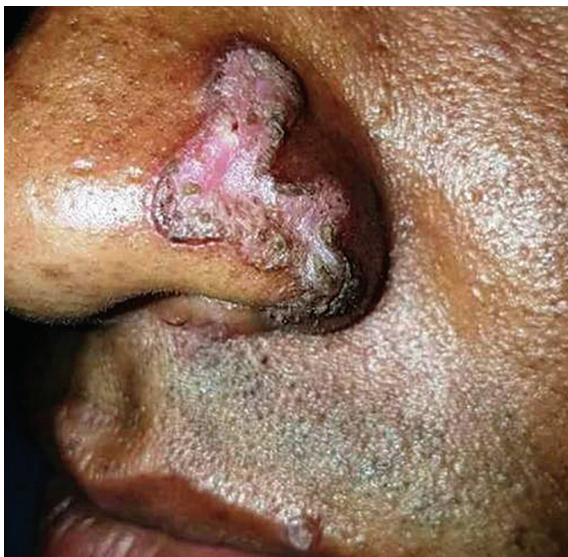

Figure 1: Clinical picture of the lesion.

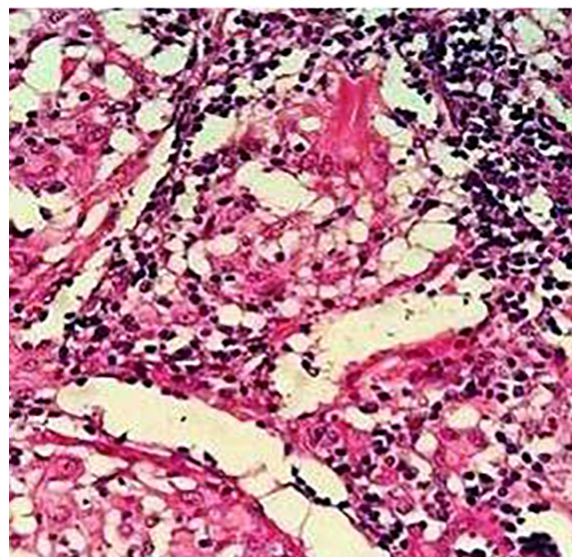


Figure 2: Non-caseating granulomas comprised of epithelioid cells and Langhans giant cells with sparse lymphocytic infiltration, magnification = 20 ×.

Answer

c. A diagnosis of lupus pernio (cutaneous sarcoidosis) without systemic involvement was made. The patient was treated with hydroxychloroquine 200 mg once daily and topical fluticasone. The patient responded with almost complete resolution at the end of seven months treatment.

DISCUSSION

Sarcoidosis is a multisystem disease that may involve almost any organ system; therefore, it results in various clinical manifestations. Cutaneous sarcoidosis occurs in up to one-third of patients with systemic sarcoidosis.¹ Recognition of cutaneous lesions is important because it provides a visible

clue to the diagnosis and an easily accessible source of tissue for histological examination.² Because lesions can exhibit varied morphologies, cutaneous sarcoidosis is known as one of the 'great imitators' in dermatology.³

Disclosure

The authors declared no conflict of interest.

REFERENCES

1. Newman LS, Rose CS, Maier LA. Sarcoidosis. *N Engl J Med* 1997 Apr;336(17):1224-1234.
2. Mohanty R, Singh SN, Bhattamishra AB. Cutaneous sarcoidosis without systemic manifestations. *Indian J Dermatol* 2009;54(5):80-82.
3. Khatri KA, Chotzen VA, Burrall BA. Lupus pernio: successful treatment with a potent topical corticosteroid. *Arch Dermatol* 1995 May;131(5):617-618.