

# Thrombosis of Bioprosthetic Right Atrioventricular Valve in a Patient with Complex Congenital Heart Disease Clinical Images

Prashanth Panduranga, Mohammed Mukhaini, Rashid Shahrabbani

Submitted: 04 Apr 2008

Reviewed: 30 April 2008

Accepted: 28 May 2008

From the Department of Cardiology, Royal Hospital, Muscat, Oman  
 Address correspondence and reprint request to: Dr. Prashanth Panduranga,  
 Department of Cardiology, Royal Hospital, Muscat, Oman  
 Email:prashanthp\_69@yahoo.co.in

**A** 32-year old Omani female with complex cyanotic congenital heart disease (complex heterotaxy with double inlet single ventricle, single atrium, severe subpulmonic stenosis, left atrioventricular(AV) valve atresia, IVC interruption, right aortic arch with LSVC, left isomerism), chronic atrial fibrillation presented with abdominal distension and lower limb edema. She had undergone right Blalock-Tausig-shunt 14 years ago which was nonfunctional. One year ago she underwent a bioprosthetic right AV valve replacement for severe right AV valve regurgitation in the United Kingdom. Her Transthoracic echocardiogram (TTE) pictures are shown (Figure 1 and 2).

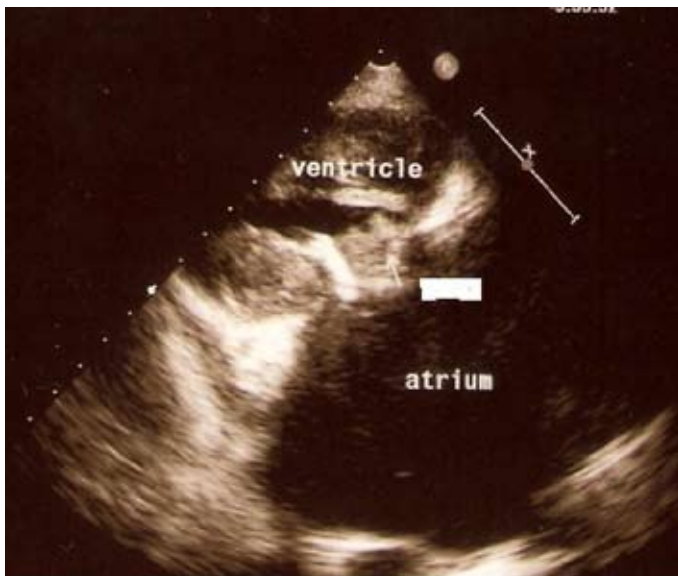


Figure 1: Transthoracic Echocardiogram (TTE)

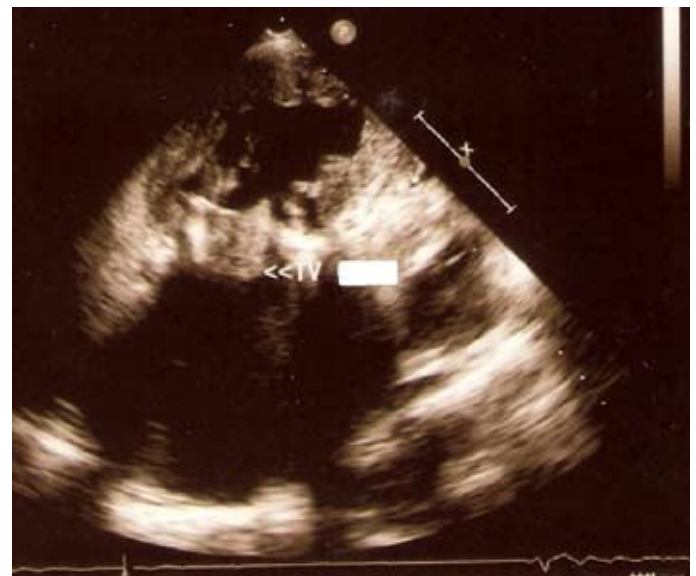

Figure 2: Transthoracic Echocardiogram (TTE)

## Questions

What is the most likely diagnosis?

1. Infective endocarditis
2. Cardiac tumor
3. Prosthetic valve thrombosis
4. Constrictive pericarditis

Answers to clinical quiz on page 200

**Answer**

Prosthetic valve thrombosis showing large clot obstructing the right AV valve.

**Discussion**

This patient presented with signs of right heart failure. She is known to have chronic atrial fibrillation on warfarin. TTE showed a large thrombus measuring 3.1 cm<sup>2</sup> in diameter seen obstructing the bioprosthetic right AV valve with absent leaflet motion (Figure 1 and 2) and an average mean transvalvular gradient of 10 mmhg. There was no regurgitation. On enquiry she admitted to have stopped taking warfarin four days ago before presenting as she had some minor epistaxis and her INR was 1.2. She discussed with cardiac surgeons and since it was a high risk surgery she was treated with streptokinase infusion 250,000 IU for 30 minutes followed by 100,000 IU per hour infusion for 24 hours. A repeat TTE done 24 hours later showed complete disappearance of thrombus (Figure 3) with freely mobile leaflets and mean transvalvular gradient coming down to 4 mmhg. The rest of her stay was uneventful and she was restarted on unfractionated heparin (UFH) with warfarin overlap aiming at high INR between 3.5 and 4.5. She was seen in the clinic six-months later and was doing well. She is planned for fontan repair in near future.

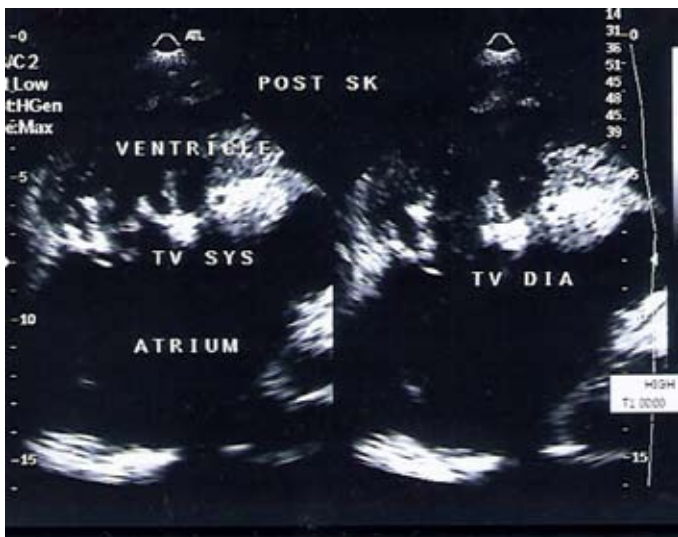


Figure 3: Repeat Transthoracic Echocardiogram done 24 hours after intusions.

Prosthetic valve thrombosis is a serious complication of both mechanical and bioprosthetic valves and has been reported to occur in 0.5% to 8% of the left-sided mechanical prosthetic valves and in up to 20% of tricuspid prostheses. Common imaging modalities used is Transthoracic/Doppler/Trans-esophageal echocardiography and/or fluoroscopy. This case shows that patients with poor anticoagulation, the right sided valve is associated with a high incidence of valve thrombosis and a nonsurgical approach (thrombolysis) is usually successful. Patients should be strictly instructed not to miss anticoagulation and should be warned about heralding signs of valve thrombosis.

According to ACC/AHA 2006 guidelines

1. Emergency operation is reasonable for patients with a thrombosed left-sided prosthetic valve and NYHA functional class III–IV symptoms and a large clot burden (>10 mm) (as in this group fibrinolytic therapy results in high embolic events 12-15%).
2. Fibrinolytic therapy may be considered as a first-line therapy for patients with a thrombosed right sided prosthetic valve and in left-sided prosthetic valve with NYHA functional class I–II symptoms, and a small clot burden (5 to 10 mm) or in NYHA functional class III–IV symptoms/ a small or large clot burden if surgery is high risk or not available. Data support the use of streptokinase, urokinase or recombinant tissue plasminogen activator as the fibrinolytic agents. Thrombolytic therapy has an initial success rate of 70% to 80% in aortic and mitral valve thrombosis.
3. Intravenous UFH as an alternative to fibrinolytic therapy may be considered for patients with a thrombosed valve who are in NYHA functional class I–II and have a small clot burden.
4. If fibrinolytic therapy is successful, it should be followed by intravenous UFH until warfarin achieves an INR of 3.0 to 4.0 for aortic prosthetic valves and 3.5 to 4.5 for mitral prosthetic valves.

**References**

- Journal of the American College of Cardiology, Vol. 48, No. 3, 2006